




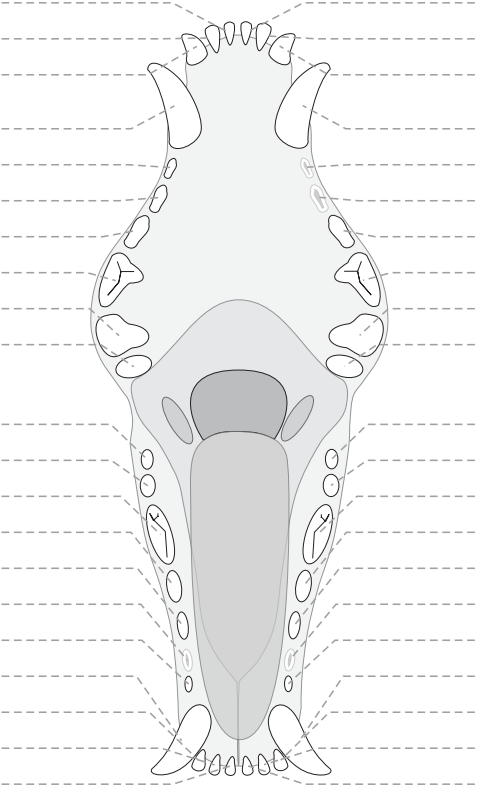





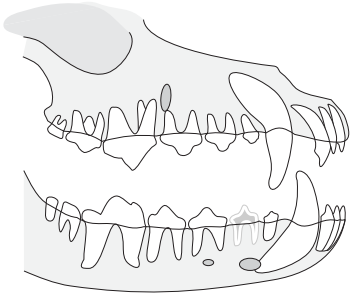
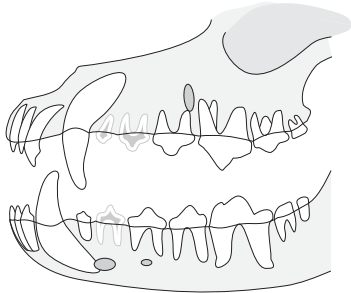







I	M	F	P	E		Evaluation dentaire						I	M	F	P	E							
						 <p style="text-align: right;">© D.C.</p>																	
					101 (I1)							201 (I1)											
					102 (I2)							202 (I2)											
					103 (I3)							203 (I3)											
					104 (C)							204 (C)											
					105 (P1)							205 (P1)											
					106 (P2)							206 (P2)											
					107 (P3)							207 (P3)											
					108 (P4)							208 (P4)											
					109 (M1)							209 (M1)											
					110 (M2)							210 (M2)											
Droite												Gauche											
					411 (M3)							311 (M3)											
					410 (M2)							310 (M2)											
					409 (M1)							309 (M1)											
					408 (P4)	308 (P4)																	
					407 (P3)	307 (P3)																	
					406 (P2)	306 (P2)																	
					405 (P1)	305 (P1)																	
					404 (C)	304 (C)																	
					403 (I3)	303 (I3)																	
					402 (I2)	302 (I2)																	
					401 (I1)	301 (I1)																	
						Légende																	
						I		Indice d'inflammation (1-4)															
M		Dent manquante																					
F		Dent fracturée																					
P		Dent de lait persistante																					
E		Extraction																					
Occlusion : non définie						General Notes:																	
Niveau de tartre : 0																							

Notes :